

1572

1773



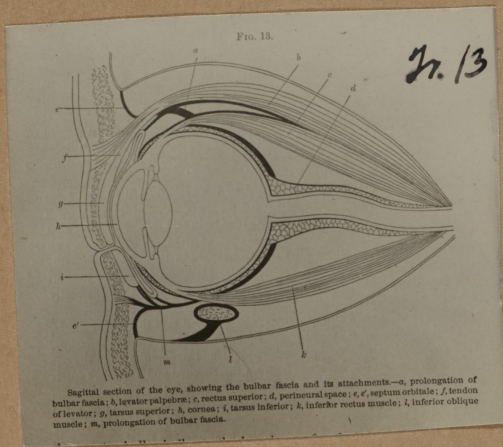
*Jr.*  
47.

Ready for duty.

#548

1573

1774



Sagittal section of the eye, showing the bulbar fascia and its attachments—*a*, prolongation of bulbar fascia; *b*, levator palpebræ; *c*, rectus superior; *d*, perineural space; *e, e'*, septum orbitale; *f*, tendon of levator; *g*, tarsus superior; *h*, cornea; *i*, tarsus inferior; *j*, inferior rectus muscle; *k*, inferior oblique muscle; *m*, prolongation of bulbar fascia.

#549

1574

1775

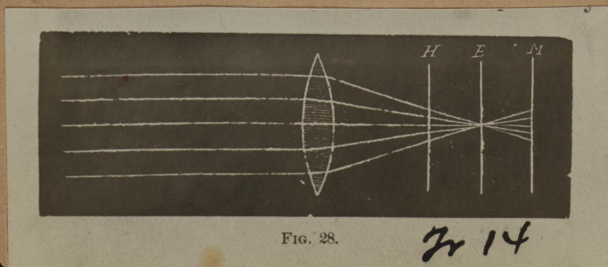


FIG. 28.

*Jr 14*

#550

PALMIS8  
page 25